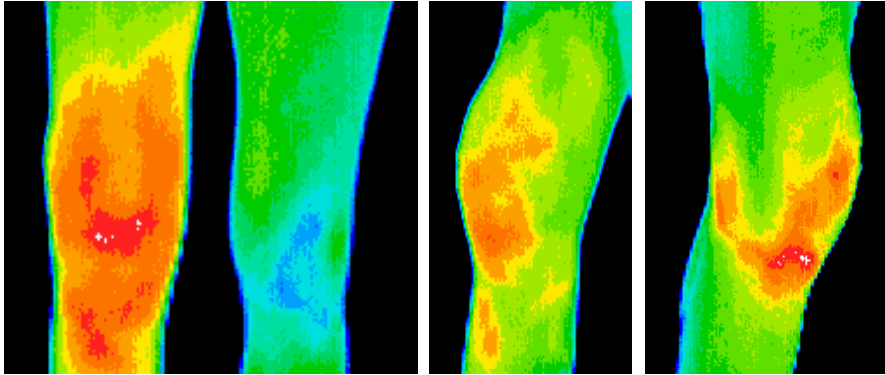


Anterior Knees

Medial Right knee

Lateral Right knee



Right knee surgery was followed with a painful effusion in the early post operative period.... Thermography confirmed a significant inflammatory reaction. 30cc of blood-stained fluid was aspirated.. Thermography can quantify all grades of joint synovitis and is able to demonstrate minimal changes due to NSAID's

Thermogenic Infections

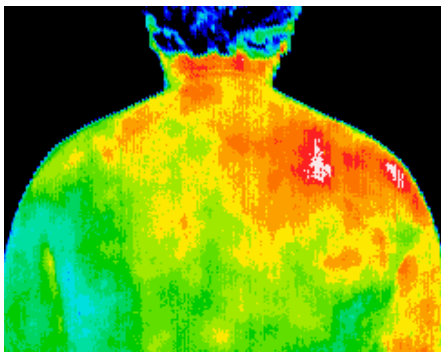
In cases of thermogenic infections (i.e. pyogenic infections), it is unlikely that DITI would be used in the diagnostic phase, as case history and physical inspection is normally sufficient to initiate a treatment protocol until pathology reports can return. DITI is particularly useful in quantifying the efficacy of a treatment protocol. In cases of depressed immune response or other at risk categories, where a practitioner is concerned with a protocol's efficacy, the effusion boundaries can be clearly quantified and measured in a DITI scan.

By progressive monitoring of an infection site, the regression and resolution of an active infection can be non-invasively monitored.

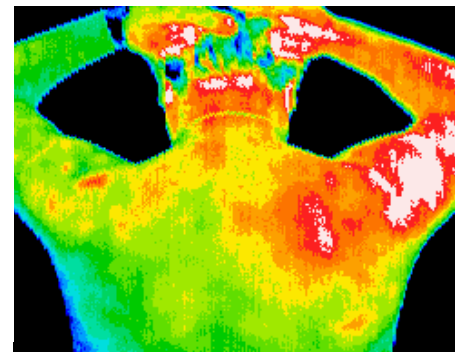
Musculo-Skeletal Dysfunction

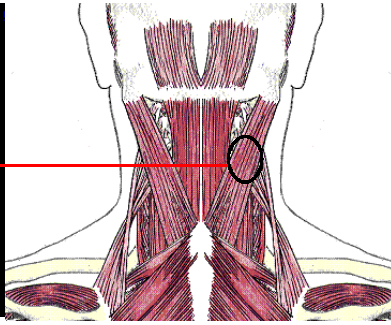
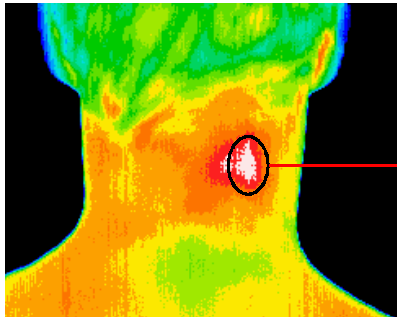
Possibly one of the more confounding patient complaints is that of musculo-skeletal dysfunction. Patient subjectivity in reporting, malingering and overlaying symptoms are just some of the confounding factors in diagnosing this group of problems.

Most musculo-skeletal problems will result in inflammation of the local tissues primarily, and surrounding tissues to a lesser extent. These conditions make excellent studies in DITI terms. Because of vascular differentials in the various soft tissues, damage to muscle, tendon, ligament and periosteum all have quite distinct thermal signatures.



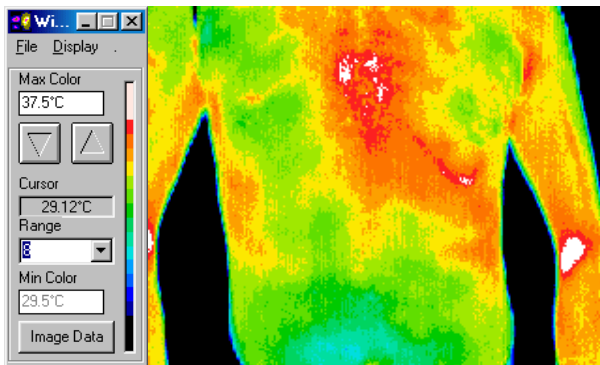
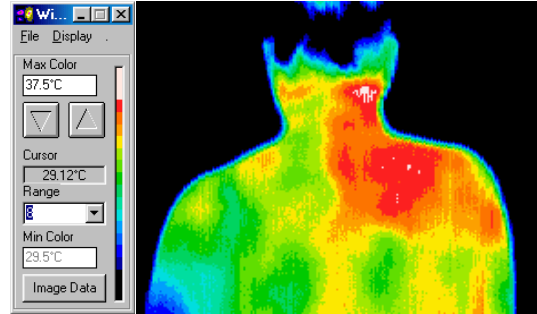
Significant inflammation throughout the right deltoid region. Thermographic findings indicated muscular rather than joint pathology





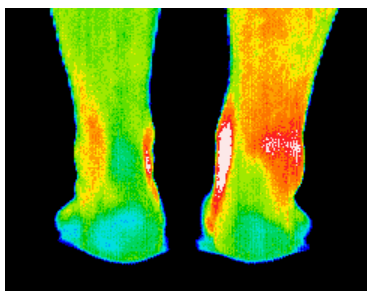
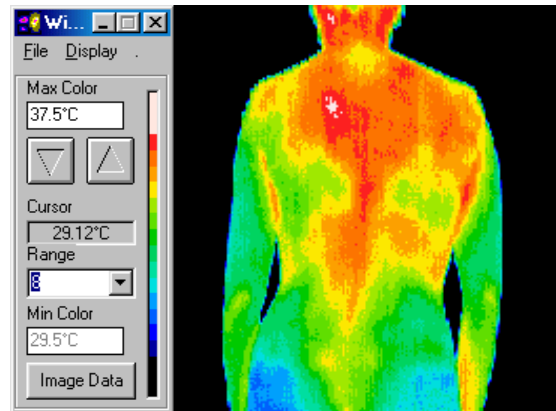
Well defined focal area of inflammation over the splenius capitis / splenius cervicis. Patients headache resolved after local IM anesthesia.

This patient with a torticollis was seen to have significant inflammation in the posterior neck and shoulder consistent with muscle spasm. There were no significant thermal asymmetries seen relating to the accessory nerve or the glands in the neck.

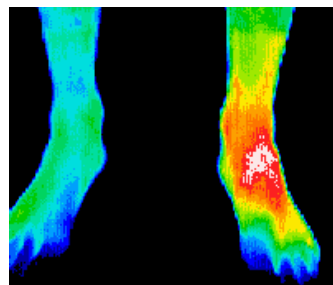


MVA patient with language difficulties, hospitalized, examined and discharged, presented two days later with chest pain. Thermology findings were sent with patient to radiology. Three fractures found in distal sternum plus small fracture in left rib.

Patient with scoliosis suffering from tension headaches. Inflammation seen over the left rhomboids was treated with remedial massage which gave relief.



Right ankle sprain with effusion



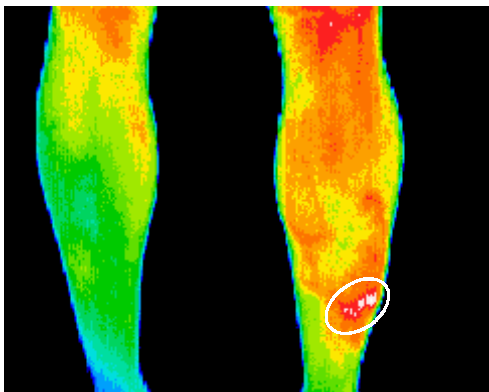
Left ankle sprain, tarsal region.

Periosteal Irritation

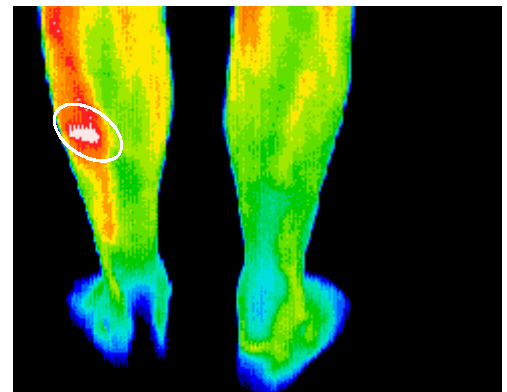
Stress fractures and periosteal micro-avulsion are perplexing problems for many practitioners concerned with radiation exposure levels of their patients. The most conclusive form of imaging for this type of injury is radio-isotope scanning (scintigraphy), which carries well documented radiation hazards.

DITI has a very high negative prediction rate with regard to stress fractures. By quantifying the presence or absence of periosteal irritation, which has a clear thermal signature, a positive DITI scan can justify a practitioner's ordering of a more invasive test. A number of practitioners who are satisfied with DITI's efficacy have begun to use just historical markers, and the DITI scans to form a diagnosis and recommend a treatment protocol.

DITI is especially useful in early cases where plain radiography often demonstrates equivocal or false negative findings, or in young patients undergoing puberty, where radiation should be kept as low as practicable.



Stress fractures - not identified on Xray but confirmed with Scintigraphy after localisation with thermography

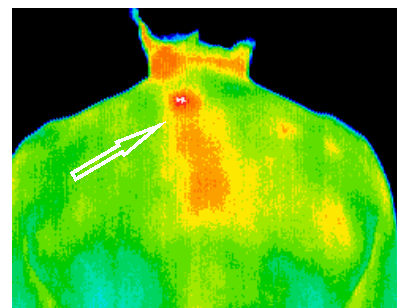
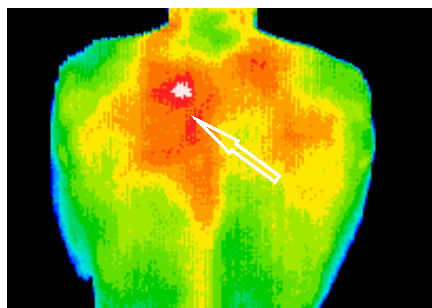
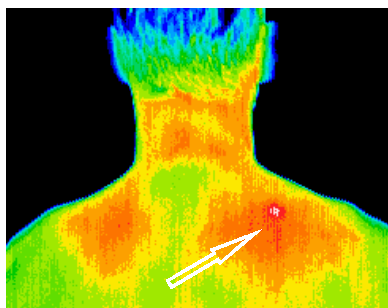


Myofascial Trigger Points

True trigger points which are active have a thermal signature that is rarely seen in any other phenomena, and is easily distinguished by historical markers. A patient complaining of a pain pattern which is following a known myofascial referral zone is a prime candidate for DITI investigation.

Once a trigger point is located and quantified, the practitioner can address the problem via their preferred protocols.

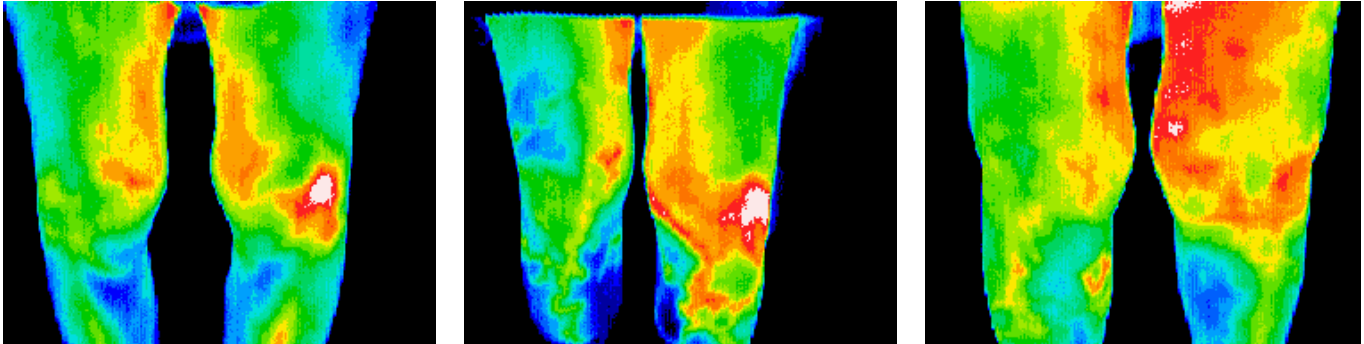
Interestingly, when a trigger point is seen, it is common to also see a diffuse hyperthermic pattern marking the referral zone, reinforcing the correct identification of a problem.



Active Arthritis

Arthritic conditions, once quantified by conventional means, can often mask other complaints. The challenge for the practitioner is one of determining whether the patient's subjective reports are likely to be of the arthritis, or another problem in the same zone.

Active arthritis shown clearly in a DITI scan as a distinct focal area of inflammation. If there is a complaint overlying an arthritic zone, DITI has a good chance of differentiating localised joint pain, sympathetic irritation (described later in the text) and other, more wide spread inflammation indicative of a separate infection or condition.



Soft Tissue Injury & Sports Injuries

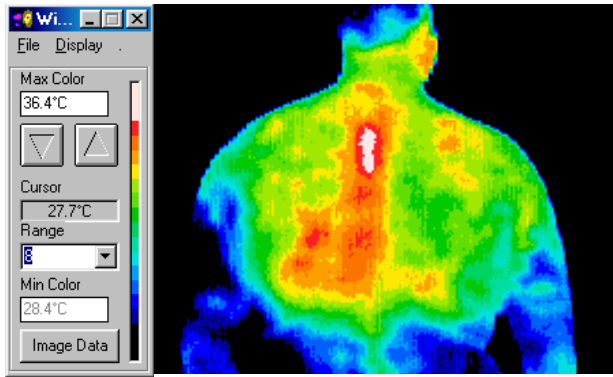
Soft tissues of the musculo-skeletal system (muscle, tendon, ligament and periosteum) have very different characteristics of vascularisation and innervation. These properties allow DITI to quantify the type of tissue injured with a high level of reliability.

Damage to highly vascular tissues like muscles will typically return a DITI scan demonstrating a focal area of irritation accompanied by a large effusive area primarily proximal to the injury site. Intramuscular haematoma will demonstrate as a combined involvement in the muscle belly and associated tendinous sheath. Extra-muscular haematoma generally exhibit enough physical signs that little doubt exists as to the nature of the injury and a DITI scan will be of little value.

Tendons, being relatively avascular and aneural exhibit very different DITI signs to muscular damage. Tendinous injury will exhibit comparatively little DITI focal area, and typically a diffuse hyperthermic response, with a proximal bias.

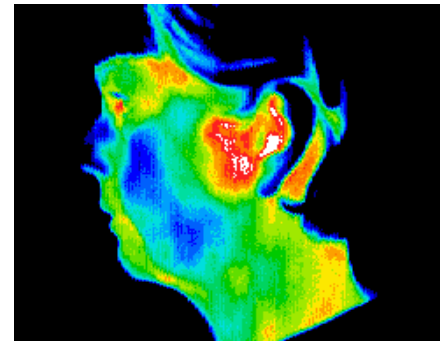
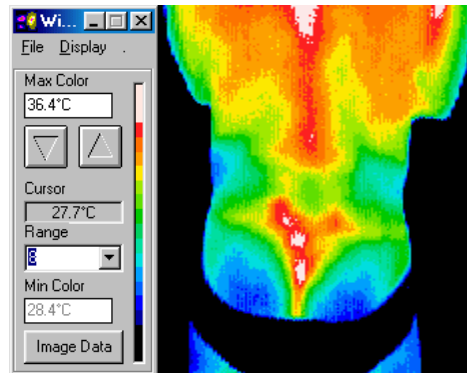
Ligamentous injury exhibits a similar pattern to periosteal irritation. Ligament lesions tend to have a very localised inflammatory response, an immediate distal radicular neuropathic hypothermia pattern, and a proximal striated hyperthermic pattern.

Traumatic vascular injury is more effectively imaged by doppler ultrasound, and as such is typically outside of DITI's expected examination frame.

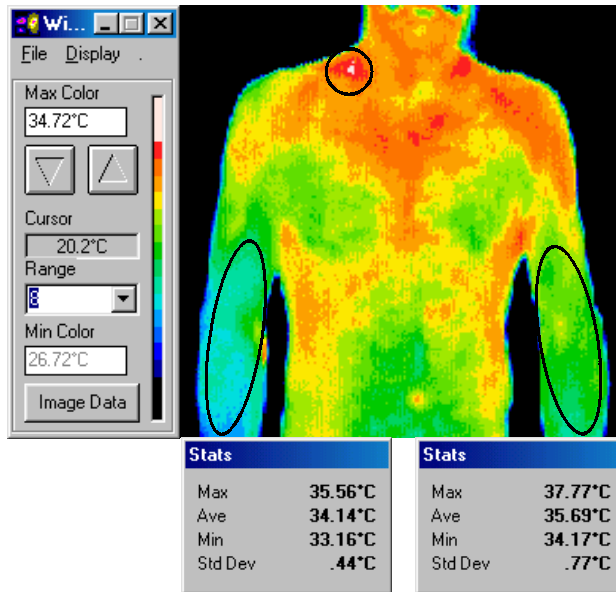


Weight lifter with a diagnosed T4 syndrome. Thermography increased the confidence in the diagnosis and established a baseline for comparative studies monitoring response to treatment.


Competitive Swimmer with pain in left gluteus maximus (swimmers nemesis)



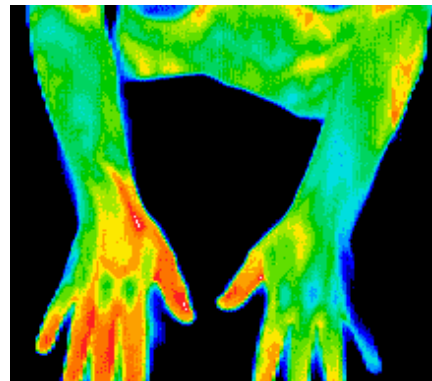
TMJ syndrome, thermography confirming diagnosis.



Right arm thrower with right arm weakness and paresthesia. Thermography showed an area of increased motor tone (sympathetic activity) in lower right arm with significant temperature differentials (hypothermia). There is also a local area of hyperthermia over the right brachial plexus. Patient was treated for brachial plexus entrapment and lower arm symptoms resolved.



Post fracture, poor healing response left ankle after cast removal, being monitored by thermography to help in decision making



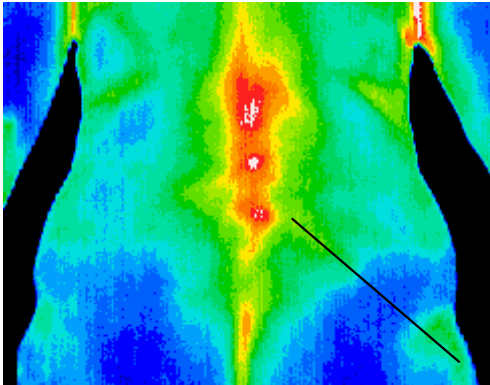
Golfer with left elbow pain that radiates distally through the ulna into the little finger. Thermography correlated well with the patients perception of pain when other tests were negative

Vasomotive Phenomena

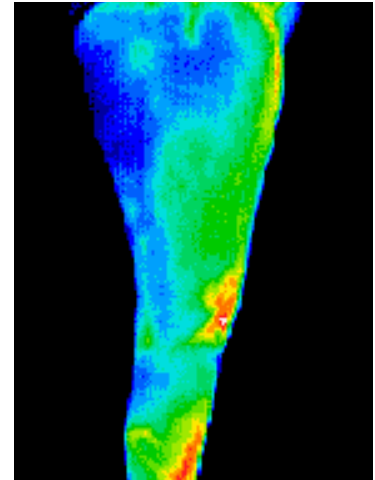
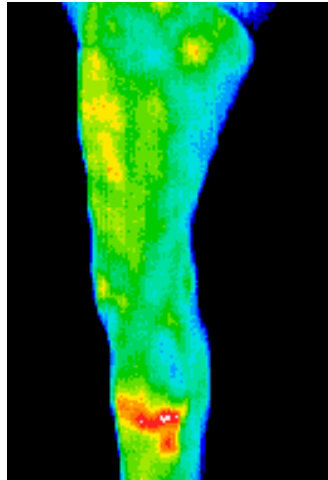
Radicular Neuropathies

Radicular neuropathies are clearly visualised by DITI scanning as an area of distinct unilateral hypothermia following a discrete sympathetic vaso-constrictive nerve supply area.

Symptoms of a radicular neuropathy may include posture dependent or independent neuralgia, anaesthesia, dysaesthesia, paraesthesia, and stiffness. As these symptoms also cover a multitude of other aetiologies, a DITI scan is a simple, non-invasive and objective modality to quantify radicular sympathetic involvement.



Right leg L3 / 4 radiculopathy



Reflex Sympathetic Dystrophy (Complex Regional Pain)

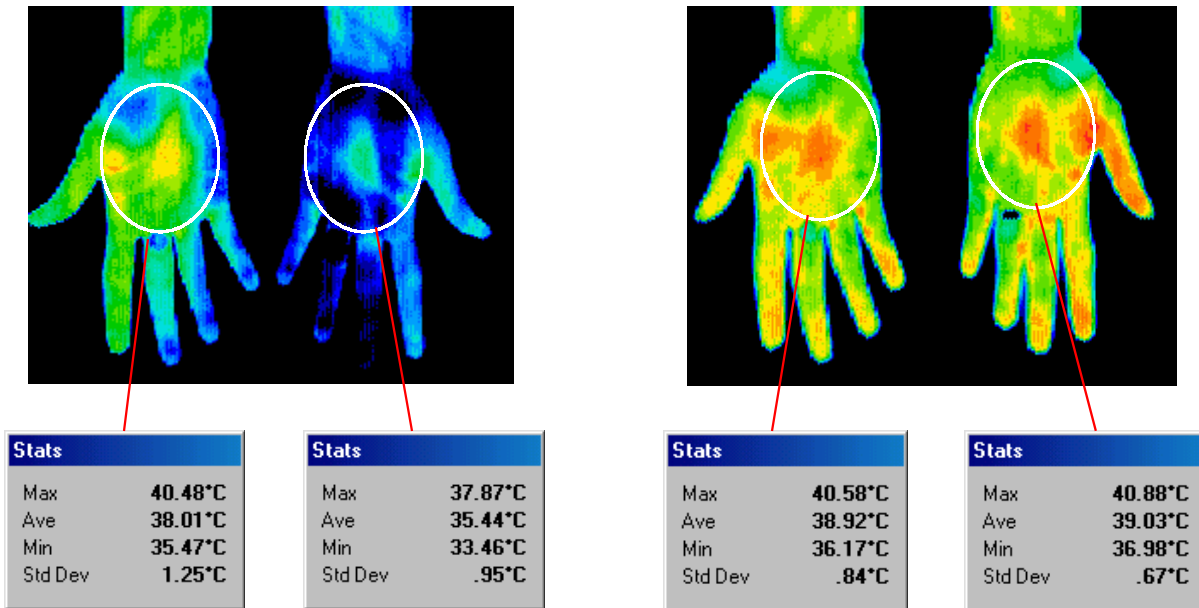
The very definition of RSD is still controversial in some quarters. Many practitioners question the diagnosis of the condition due to lack of objective and reliable evidence. Hooshmand (1993) in his encyclopaedic work, “Chronic Pain: Reflex Sympathetic Dystrophy. Prevention and Management”, states that ‘Infrared Thermography is the most sensitive test in the diagnosis of RSD’. He goes on to state that no other testing modality can match thermography in the detection of RSD.

RSD has a very distinct DITI signature, where there is a well defined border to the hypothermic zone, which will normally give a ‘glove’ or “sock” like image of hypothermia. In cases where RSD is suspected, a cold challenge stress test is applied.

The suspect area is scanned for thermal stability, and once established a cold challenge is applied. The patient has a non-affected body part immersed in water of approx. 4 degrees Centigrade. This causes the sympathetic nervous system to respond, and restrict the micro-dermal circulation over the body. This sympathetic vasoconstriction will not be observed in an area demonstrating true RSD. If the symptomatic area shows any reduction in temperature over the three minutes of the cold challenge, RSD is determined not to be affecting the area. This tends towards the idea of a “simple” neuropathy. The reliability of the cold stress is guaranteed by the simultaneous scanning of asymptomatic zones, and ensuring that these zones respond with a reduced vaso-motion response.

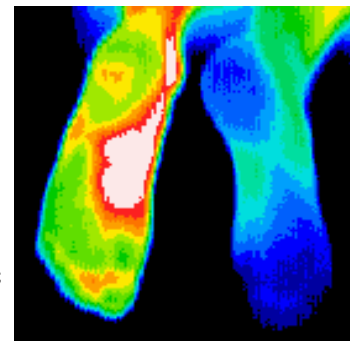
RSD patient with a 'glove like' hypothermia of the left hand. A temperature differential of 1.5 °c is considered significant, this patient presented with a 5 °c asymmetry. Cold stress test showed sympathetic function in the right hand but non in the left.

After treatment thermography showed good thermal symmetry and cold stress showed sympathetic function in both hands.



Complex Regional Pain Syndrome right foot, significant increase in sympathetic motor tone right foot 3.7°c colder than left foot. A cold stress test was positive, (no sympathetic change).

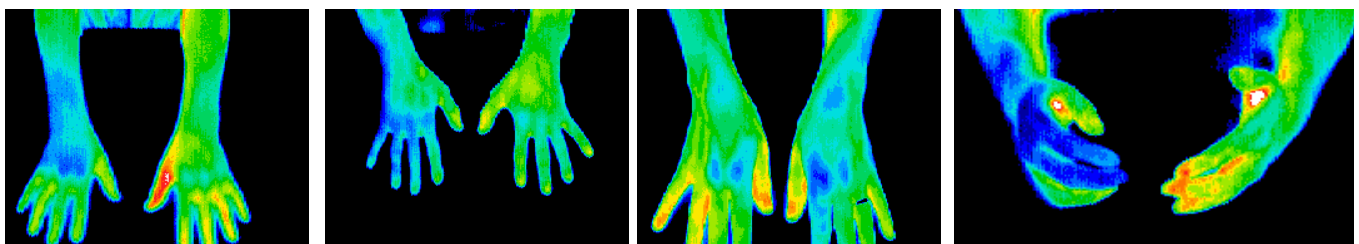
CRPS developed in the right foot after a fractured calcaneum 18 months previously. Weight bearing was painful. The diagnosis of CRPS was missed initially since nuclear imaging was not typical of CRPS. Some cases of CRPS are misdiagnosed as psychological or hysterical pain states. Thermography is able to show characteristic changes if utilized.



Neuropathological Referrals

Neuropathological factors in clinical assessments are made difficult by the requirement for subjective patient description of their sensations. Because DITI yields objective results, reliance on a patient's subjective reporting is far lessened, and the practitioner is able to better understand and scale the reported symptoms.

Factors capable of interfering with the transmission of action potential will show an asymmetrical thermal signature along the path of that nerve. The neural vasomotion factors will typically exhibit alteration along a specific dermatomal pathway in the case of vertebro-costal problems, and in the specific regions of supply for problems interfering with discrete nerve pathways.



Vascular Phenomena

Angiogenesis

Neoplastic alterations of cells have demonstrated accompanying high levels of interstitial angiogenic stimulating compounds, particularly of the prostaglandin types (PEG1 & PEG2). Gullino (1992) states 'The thin walled vessels that are present in tumours consist almost entirely of basement membrane with a single cell layer, i.e. endothelium.' He goes on further to state, 'the newly formed vessels produce a chaotic, disorganised network, with tortuous vessels, often sinusoidal in nature and always thin walled, traversing the tumour mass. It seems likely that the rare vessels seen in a tumour with a well-developed multi-layered wall are those that have been parasitised and engulfed by the expanding tumour mass.' (pp. 160-161)

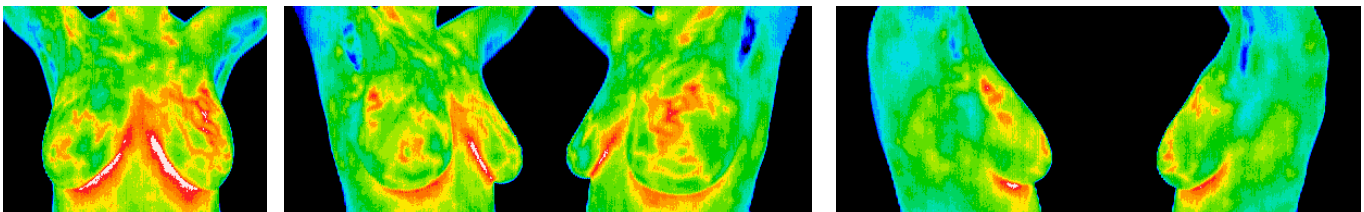
In suitable tissues (the breast in particular), these factors combine to exhibit a clear thermal signature due to

- Increases in vessel size servicing the neoplasm form a demonstrable DITI asymmetry.
- The chaotic nature of the capillary structure leads to a lack of graduated thermal transition ('smooth' thermal signature), as expected in normal tissues.
- The lack of smooth muscle tissue in the neovascularity demonstrates a comparative vasomotion thermal signature that does not respond in similar fashion to the surrounding 'normal' vascular structures. Eliciting a sympathetic constrictive response by immersion of a body part (usually a hand and wrist) in cold water will demonstrate a vasomotion differential in the effected area.
- In more advanced neoplastic formations, the chaotic tissue structure with depressed metabolism in tissues removed from the vascular supply will often demonstrate a hypothermic core. Depending on position, the hypothermic displacement will show in a DITI scan.

Many of the so-called 'false positives' of DITI breast screening are often 'true positive' findings of angiogenesis preceding actual tumour development. Detection in these early stages is unreliable by conventional means, often due to the fact that the tumour has not developed sufficient density.

DITI breast screening is particularly useful to:

- Women who are under 40
- Women who for any reason can not or will not have a mammogram
- Women who are outside of the mammographic screening guidelines due to surgical procedures or contra indicating reasons.



Standard views for a breast study: vascular patterns in the upper quadrants of the left breast are consistent with angiogenesis and would justify further investigation and regular comparative thermography to monitor changes.